IIH Life: A prospective longitudinal cohort study of Idiopathic Intracranial Hypertension

Mark Thaller[1,2,3], Victoria Homer[4], Susan P Mollan[1,5], Alexandra J Sinclair[1,2,3]

1. Metabolic Neurology, Institute of Metabolism and Systems Research, University of Birmingham, Edgbaston, B15 2TT, United Kingdom (UK). 2. Department of Neurology, University Hospitals Birmingham NHS Foundation Trust, B15 2TH, UK. 3.Centre for Endocrinology, Diabetes and Metabolism, Birmingham Health Partners, B15 2TH, UK. 4. Cancer Research (UK) Clinical Trials Unit, University of Birmingham, Birmingham, B15 2TT, UK. 5. Birmingham Neuro-Ophthalmology, University Hospitals Birmingham NHS Foundation Trust, B15 2TH, UK.

Contact: a.b.sinclair@bham.ac.uk @IIHDrBirmingham; mark.thaller@nhs.net @MarkHeadache

Introduction

There is limited longitudinal data evaluating visual and headache outcomes in Idiopathic intracranial hypertension. Large prospective studies are required to help characterise key outcomes to help guide clinicians.

Aims and Objectives:

- Establish the long term visual and headache outcomes in idiopathic intracranial hypertension?
- Investigate for prognostic factors for long-term visual and headache outcomes

Methods

- IIH:Life is a prospective observational cohort study.
- IIH patients seen at the University Hospital Birmingham (UHB) between 2013 and 2021.
- Patients were excluded if there was a secondary cause for intracranial hypertension, IIH without papilloedema (IIHWOP) or alternative diagnosis.
- Visual outcomes assessed were retinal nerve fibre layer thickness (RNFL), total retinal thickness (TRT) of the optic nerve head and macular ganglion cell layer volume (GCL) on Optical Coherence Tomography (OCT). Humphrey visual field perimetric mean deviation (PMD) and LogMAR visual acuity were also assessed.
- Headache outcomes assessed were monthly headache days, monthly migraine-like days, headache severity and Headache Impact Test 6 (HIT-6) score.

Express Summary

What are the long term visual and headache outcomes in idiopathic intracranial hypertension?

Findings

- Long term visual outcomes in the non-surgical cohort are excellent.
- Headache burden remains high.
- Papilloedema height appeared to be associated with deterioration in macular ganglion cells and visual field mean deviation.
- Prognostic factors:
  - Vision: change in BMI and disease duration
  - Headache: daily headache at presentation and personal migraine history

Results

- 555 patients were evaluated from the IIH:Life database with 490 having a confirmed IIH diagnosis.
- 98% were women with a mean BMI of 38kg/m^2.
- 319 (65%) had active papilloedema at first tertiary neuro-ophthalmology review, with 171 (35%) in ocular remission.

Figure 1. Visual outcome trajectory in medically managed IIH patients according to disease status (active v remission)

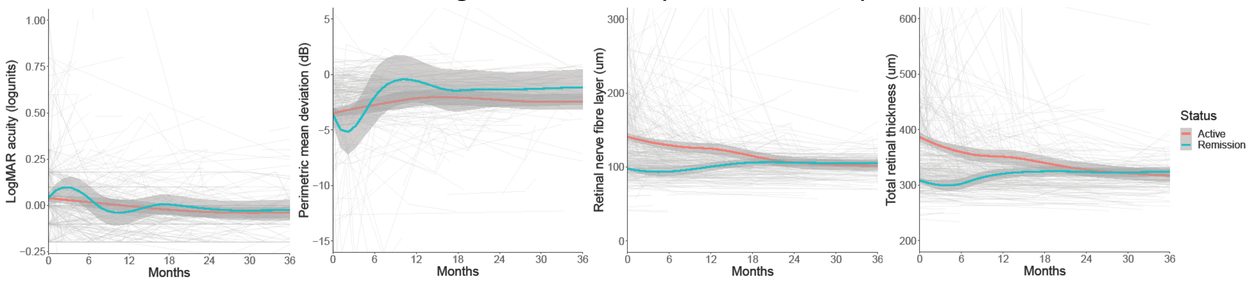

Figure 2. Headache outcome trajectory in medically managed IIH patients according to disease status (active v remission)

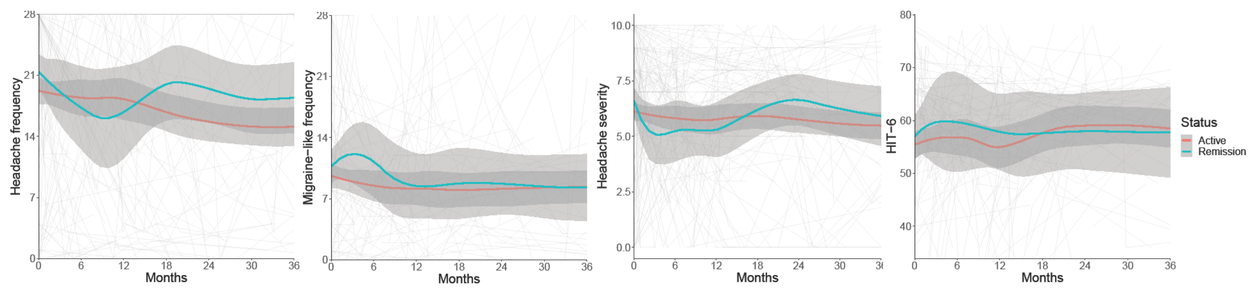

Figure 3. Change in mean deviation, macular ganglion cell layer volume and body mass index in the whole IIH cohort according to highest RNFL

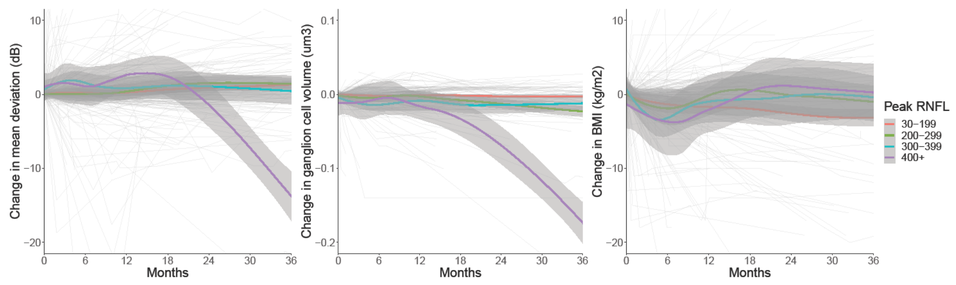

Table 1. Baseline demographics

	All IIH	Active	Remission	Medical	Surgical
IIH patients (n)	490	319	171	426	64
Surgical intervention (n)	64	38	26		
Females (n)	481	314	167	420	61
Age (years)	31.5 (9.4)	31.0 (9.0)	32.4 (10.2)	31.6 (9.5)	30.6 (9.0)
BMI (kg/m^2)	38.1 (9.3)	38.5 (9.5)	37.3 (8.8)	37.8 (9.5)	40.2 (7.9)
CSF opening pressure (cmH_2O)	36.5 (6.0)	31.0 (9.4)	38.3 (5.9)	34.7 (4.5)	35.3 (7.1)

- Significant decrease in RNFL in those with active disease at baseline visit compared to ocular remission.
- Increase in BMI was associated with a worsening of papilloedema and visual field mean deviation.
- In the majority of people visual outcomes improve over time.

- Headache outcomes showed marked variability with a high headache burden.
- Daily headache at baseline visit and personal migraine history were the two prognostic markers for worse outcomes.

- In this real-world dataset, use of intracranial pressure (ICP) lowering medications was variable, therefore in this analysis the use of ICP lowering medications do not appear to be disease modifying in the longer term. The data presented here warrants further evaluation before a change in clinical practice.

Conclusion

- The headache burden was high in this cohort and likely requires complex headache management.
- Patients with severe papilloedema at higher risk of ganglion cell loss and long-term visual field impairment.
- The data presented here, in terms of ICP lowering medications, warrants further evaluation before a change in clinical practice.
- Long-term visual outcomes in the non-surgical cohort were excellent.